c) Observation on vulva & perineum, any abnormalities and response of woman. d) Color, odor, amount and consistency of lochia.				
25-Give health teaching about self-perineal care.				
Procedure score				
Date				

Student signature: **Instructor signature:**

Portogram

Goal:

At the end of this lecture, each student should acquire complete knowledge, skills and positive attitude toward portogram and

how to apply it in labor unit.

Objectives:

At the end of this lecture, the student will be able to:

- Define of portogram.
- Define purpose of portogram.
- Define component of portogram.
- How to apply portogram.
- Acquire knowledge on cases related portogram.

Out lines

- Definition of the portogram.
- Purposes of the portogram.
- Components of the portogram.
- Examples of some comments on portogram.
- Reference

Definition:

Is a graphical presentation of the progress of labor and fetal, maternal condition during labor .it is the best tool to detect whether the labor progress normally or abnormally and detect occurrence of fetal distress.

Purposes

1- To assess progress of labor.

2- To assess fetal and maternal condition.

3- Early detection of fetal or maternal distress.

4- Early detection of abnormal labor patterns (prolonged or obstructed labor).

5- Assist in early decision for transfer, augmentation, or termination of labor.

6- Portogram can be highly effective in reducing complications from prolonged labor for the mother (postpartum hemorrhage, sepsis, uterine rupture) and protect the newborn from (death, asphyxia).

Component of Portogram:

1) Part 1: Fetal Condition (at the top). At the top write (Name, age, date, time of admission, and diagnosis (parity, Gravida).
2) Part 2: Progress of Labor (at the middle).
3) Part 3: Maternal Condition (at the bottom).

Part 1: Fetal Condition

a. Fetal heart rate.

b. The condition of the membrane and liquor.

c. Moulding of the fetal skull bones.

a. Fetal heart rate.



Basal fetal heart rate = (120-160 b/m)

- >160 beats/min = tachycardia
- <120 beats/min = bradycardia
- <100 beats/min = severe bradycardia

b. The condition of the membranes and liquor

1- Intact membranes .....**I**

2- Ruptured membranes + clear liquor .....**C**

3- Ruptured membranes + meconium stained liquor .....**M**

4- Ruptured membranes + blood stained liquor ..... **B**

5- Ruptured membranes + absent liquor ..... **A**

c. Moulding of the fetal skull bones.

- Molding is an important indication of how adequately the pelvis can accommodate the fetal head.
- Increasing molding with the head high in the pelvis is an ominous sign of cephalopelvic disproportion (CPD).

1) Separated bones. Sutures felt easily Write on partogram O
2) Bones just touching each other Write on partogram +
3) Overlapping bones (reducible) Write on partogram ++
4) Severely overlapping bones (non reducible). Write on partogram +++

Part 2: Progress of Labor (at the middle)

a- Cervical dilatation.

b- Descent of the fetal head.

c- Uterine contractions.

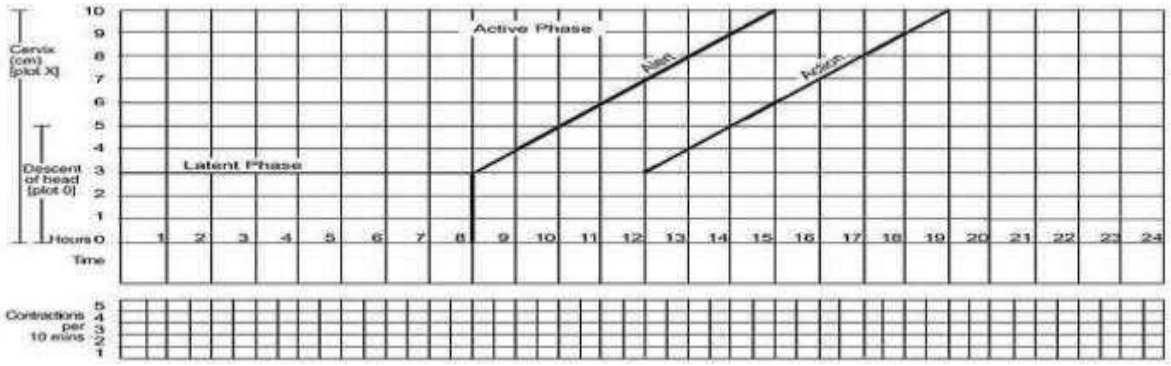

a- Cervical dilatation.

- It is an essential part of the partogram, it offers the chance of early detection of slow progress of labor, recorded with an **(X)** mark.
- It is divided into a latent phase and an active phase

Latent phase: it starts from onset of labor until the cervix reaches 3 cm dilatation, once 3 cm dilatation is reached, labor enters the active phase.



- It lasts 8 hours or less.
- Contractions lasting < 20 seconds.
- Contractions at least 2/10 min.

Active phase: it starts from the cervix 3 cm dilatation until the cervix reaches to the full dilatation 10 cm. The cervix should dilate at a rate of 1 cm / hour or faster.

- It lasts 4 hours or less.
- Contractions lasting > 40 seconds.
- Contractions at least 3 / 10 min.

Alert line (health facility line)

- The alert line drawn from 3 cm dilatation, if a woman arrives in the active phase of labor, recording of cervical dilatation starts on the alert line.

- When progress of labor is normal and satisfactory, plotting of cervical dilatation remains on the alert line or to left of it.
- Moving to the right of the alert line means referral to hospital for extra vigilance.

Action line (hospital line)

- The action line is drawn 4 hours to the right of the alert line and parallel to it.
- This is the critical line at which specific management decisions must be made at the hospital.

b- Descent of the fetal head.

- It should be assessed by abdominal examination immediately before doing a vaginal examination, using the rule of fifth to assess engagement.
- The rule of fifth means the palpable fifth of the fetal head are felt by abdominal examination to be above the level of symphysis pubis.
- When 2/5 or less of fetal head is felt above the level of symphysis pubis, this means that the head is engage, and by vaginal examination, the lowest part of vertex has passed or is at the level of ischial spines.
- Descent of the fetal head is plotted with an (**O**) mark.
- Assessing descent of the fetal head by vaginal examination; 0 station is at the level of the ischial spine (Sp).

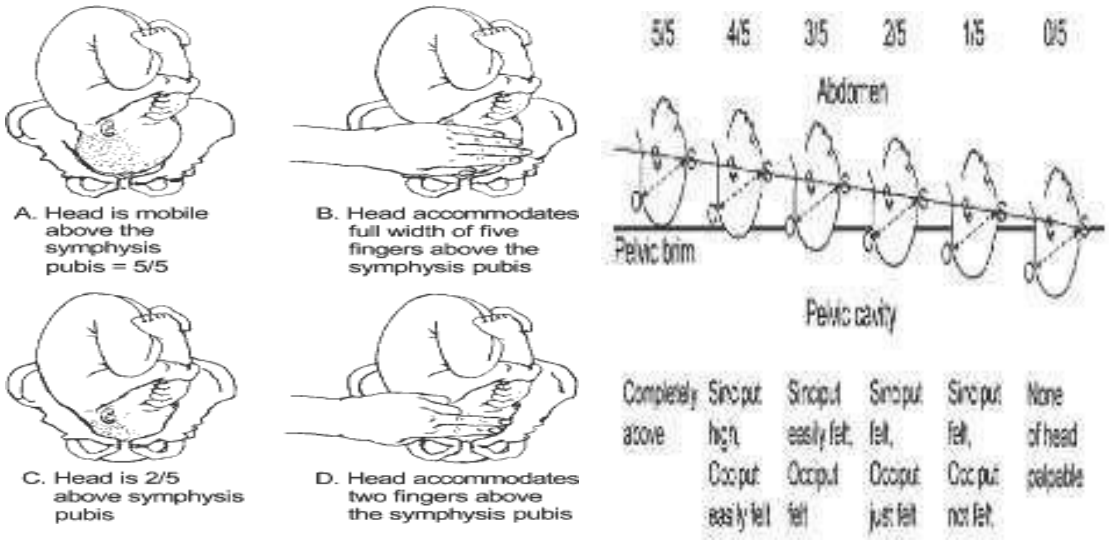

c-Uterine contraction

- The contraction wave of the uterus begins in the fundus, which contains the greatest concentration of myometrial cells and moves downward throughout the entire myometrium.
- Observations of the contractions are made every hour in the latent phase and every half-hour in the active phase, each square represents one contraction.

Palpate number of contractions in ten minutes and duration of each contraction in second's uterine contractions and plotted with differential shading:

1- Less than 20 seconds: 

2- Between 20 and 40 seconds: 

3- More than 40 seconds:

Part 3: Maternal Condition (at the bottom)

- Assess maternal condition regularly by monitoring:

a- Drugs, IV fluids, and oxytocin, if labor is augmented

b- Pulse, Blood pressure and Temperature

c- Urine volume, analysis for protein and acetone

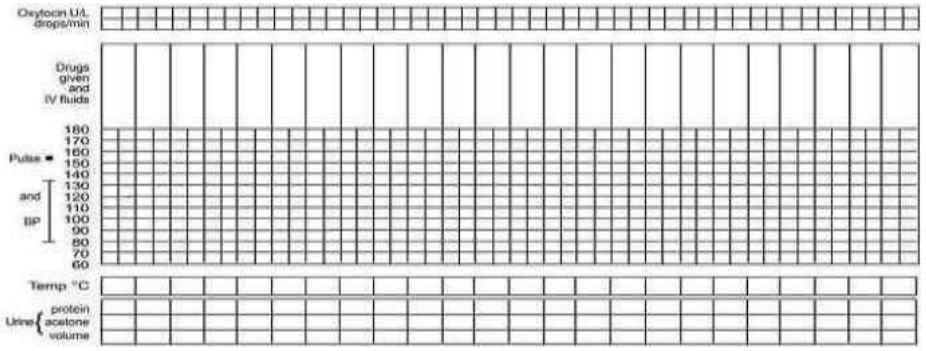

Comments on partogram

1. If FHR of the fetus increased or decreased (there is fetal distress and need action or need cesarean section C.S)
2. If there is excessive molding (these indicate Cephalo pelvic

disproportion CPD and may lead to fetal distress and need C.S)

3. If the membrane ruptured and meconium present (there is fetal distress need monitoring FHS and need action C.S)
4. If there is slow cervical dilatation progress (indicate prolonged labor) or cervical dilatation stopped (identify the cause and manage it)
5. If the head high there I no head descend (CPD and need C.S)If there is weak contraction (indicate the need for oxytocin with monitoring FHS)
6. If the urine had protein with increase Blood pressure (this case may have preeclampsia and need management and monitoring).

Partogram

Action	First Trial		Second Trial	
	Done	Note Done	Done	Note Done
1. Prepare the equipment needed.				
2. Explain the procedure and way of assessment to the woman.				
3. Record the mother s' admission data.				
4. Assess and record the fetal condition: • Fetal heart rate. • Membranes condition. • Moulding.				
5. Assess and record labor progress as the following: • Cervical dilation. • Descent of the fetal head. • Uterine contractions				
6. Use of action and alert lines: • Draw the alert line by taking a ruler and drawing oblique line from.				
7. Assess and record maternal vital signs.				
8. Record I.V fluids , drugs				
9. Record syntocinon as the following: • Calculate the number of units in 500 ml Dextrose or other IV fluid. • Adjust the rate of infusion per minute.				
8. Record urine volume and abnormal constitutes (albumin, acetone and blood).				
Producer				
Date				
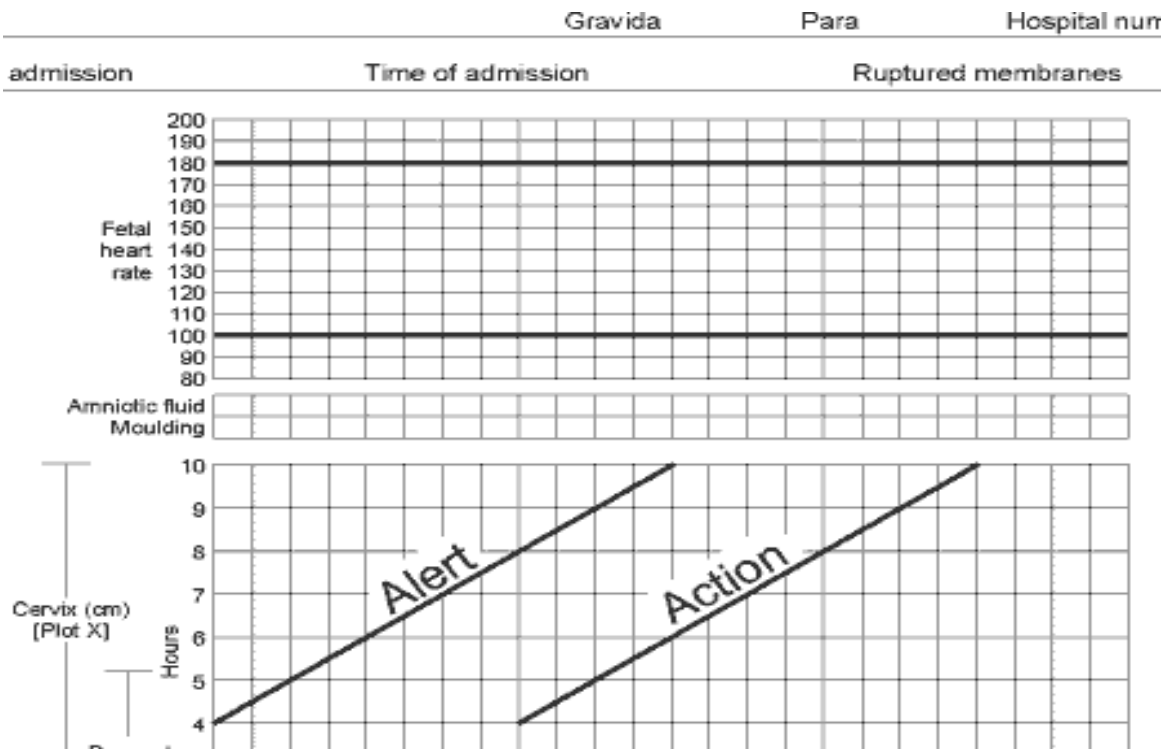
Student name: Instructor name